

Area-dependent enlargement ratios of panoramic tomography depending on incorrect patient positioning and its significance for implant dentistry; Appendix: Horizontal magnification factors at the apical implant step

Germán Gómez-Román, Dr. med. dent.*, Dieter Lukas, MSc.**, Roman

Beniashvili, Dr. med. dent.***, Willi Schulte, Prof., Dr. med. dent.****

* Associate Professor, Department of Prosthodontics (Medical Director: Univ.-Prof. Dr. med dent. H. Weber), Dental School, University of Tübingen; and Former head of Collaborative Research Department A7 (Surgery of Dental Implants, Control and Documentation) of Special Research Project SFB175 "Implantology", (German Society of Research),

Osianderstr. 2-8, D-72076 Tübingen, Germany, Fax No. ++49 7071 293982.

**Research Fellow, Clinic of Oral and Maxillofacial Surgery (Medical Director: Univ.-Prof. Dr. med., Dr. med. dent. S. Reinert), Dental School, Eberhard-Karl-University, Osianderstr. 2-8, D-72076 Tübingen, Germany, e-mail: lukasd@uni-tuebingen.de

*** Dentist, former Department of Oral Surgery and Periodontology, Dental School, University of Tübingen, Osianderstr. 2-8, D-72076 Tübingen, Germany

****Professor Emeritus, Department of Oral Surgery and Periodontology, Dental School, University of Tübingen; and Former Speaker of Special Research Project SFB175 "Implantology" (German Society of Research), Osianderstr. 2-8, D-72076 Tübingen, Germany

Abstract

Objective: The behavior of the vertical and horizontal magnification factors in optimum positioning and incorrect positioning for panoramic radiography images has been published previously. This appendix extends the investigation to the horizontal magnification factors *at the apical implant step*, which are important to determine the distance between the roots for the single-tooth gap where the teeth are closely spaced. **Method and materials:** Various degrees of incorrect positioning of a

macerated skull are specified with a sliding and tilting table on the retainer. **Results:** The vertical magnification is exceeded by the horizontal magnification factors for all types of incorrect positioning, including at the apical implant step. Here the magnification at the coronal implant end is mostly exceeded. The variation in the influence of incorrect positioning of the skull at both implant ends results in significantly distorted displays in the x-ray image. **Conclusion:** When these results are considered, the panoramic radiography technique is demonstrated to be a suitable procedure for both pre-implant diagnostics and also for monitoring the procedure and the success of the treatment. Because the patient positioning in the horizontal dimension has a great influence on the magnification factors, particularly in the interforaminal region, imaging of dense metallic structures of known dimensions, such as 5-mm balls, can also continue to be recommended. However, stepped implants, which have a smaller apical diameter, are recommended for situations where the roots of the teeth are closely spaced to prevent injury to the natural teeth.

Key words: area-dependent; imaging technique with incorrect positioning; Frialit-2; enlargement, dental implantology; panoramic radiography; radiographic measuring

Introduction

The significance of panoramic radiography for pre-implant diagnostics has been described in detail for orthograde positioning in the first section of this article ¹. The second section ² of our work presents the magnification and distortion caused by asymmetrically incorrect patient positioning and the third section ³ that caused by symmetrically incorrect patient positioning. This supplementary section covers the change in magnification at the apical implant step caused by incorrect patient positioning and the resulting distortion.

Material and Methods

The tests were conducted on an average-shaped, edentulous, macerated skull. 26 Frialit™-2 stepped cylinder implants were inserted in the skull. The complete procedure, including the radiology technique, has been described in detail in the previous sections of this work, as well as the cephalometric analysis, measurements of the implants and the statistical methods used.

Results

The magnification factors of the incorrectly positioned panoramic radiography images are based on the results with orthograde position and placed in relation to the reproducibility of the settings at the x-ray unit ⁴. All magnification factors with an incorrect position were calculated from six individual values for every one of the four degrees, and with an orthograde position from 18 individual values.

The vertical magnification is exceeded by the horizontal magnification factors for all types of incorrect positioning, including at the apical implant step and in part the magnification at the coronal implant end. The extreme deviations in comparison to the orthograde positioning are summarized in [Table 1](#).

Sliding in the transverse plane. The dependence of the horizontal apical magnification factor on the region and degree of sliding to the left is summarized in [Fig. 1](#). No significant influence at the level of reproducibility by incorrect positioning on the magnification factor can be noted in the first quadrant. In the fourth quadrant the magnification is greater in comparison to the orthograde setting, increasing with the degree of sliding. In contrast, the right quadrants show a significant decrease in the magnification factors. The changes are generally similar at the coronal and the apical implant step.

Sliding forwards in the sagittal plane. The horizontal magnification factor at the apical implant step is significantly reduced with the sliding of the skull ([Fig. 2](#)). This change is particularly marked in the anterior jaw sections. In the case of the second left incisor the 1.0 line is not even reached. The changes at the coronal and the apical implant step are also generally similar with this incorrect positioning.

Sliding backwards in the sagittal plane. During sliding the horizontal magnification factors in both jaws clearly increase with increasing incorrect positioning of the skull, and the increase is significant in the anterior region ([Fig. 3](#)). In contrast to the horizontal magnification at the coronal implant step, this tendency is clear apically only in the front tooth sections.

Tilting around the dorso-ventral. In the right maxillary and mandibular halves a reduction of the magnification factor at the apical implant step can be noted when tilted ([Fig. 4](#)). The magnification factor has a tendency to increase in the left

quadrants. On the right the changes are significant with minor incorrect positioning, but on the left only from 4.5° , and in the second quadrant only at a few implant sites. The magnification factor is changed somewhat more by incorrect positioning of the skull apically than at the coronal implant step.

Rotation around the cranio-caudal axis. The magnification factor increases with the increase of the angle of rotation in the right maxillary and mandibular halves, while it is reduced in left jaw halves (Fig. 5). The magnification changes, particularly on the left, are clear and significantly different from the orthograde setting. In the third quadrant posterior the magnified view of the object typical for panoramic imaging tends to disappear (< 1.0). The influence of incorrect positioning on the horizontal magnification at the coronal and at the apical step is approximately of the same magnitude.

Tilt upwards around the transverse axis. During tilting the horizontal magnification factor is reduced significantly in all implant regions and in some cases in the third quadrant falls below the value 1.0 (Fig. 6). The mandible is more sensitive to tilting than the maxilla. The effects on the horizontal magnification factor at the apical implant step are greater than at the coronal implant step.

Tilt forward-downward around the transverse axis. During tilting the horizontal magnification factor increases gradually at the apical implant step in all implant regions (Fig. 7). This change is only significant in the anterior implant regions in the mandible and for the first incisors in the maxilla. The influence of this incorrect positioning on the horizontal magnification factor is greater at the apical implant step than at the coronal.

Discussion

The horizontal magnification at the apical implant step is greater than at the coronal step in the entire maxilla. It is generally greater in the mandible, but in the lateral dental region less than or equal to the magnification at the coronal step. The different horizontal magnification at these two steps is connected to the fact that the apical step in the maxilla is further from the film because of the oro-vestibular inclination of the implants resulting from the curve of the alveolar ridge, while in the mandible it is closer to the film than the coronal and so is shown magnified. This has

previously been demonstrated by Setz et al. ⁵ in a clinical study on IMZ implants and mathematically proven by Tronje et al. ⁶. An additional explanation is also given in the study conducted by Hayakawa et al. ⁷, which demonstrated that objects more distant from the film are shown more distorted than those closer to the film.

Measurement of the coronal and apical implant steps allows the magnification and distortion effects occurring as a result of incorrect positioning to be calculated individually for every panoramic radiography image, as described in detail in section 1. The results can be transferred to the peri-implant translucence. Consistent application allows a more precise assessment of the actual course of an increasing bone defect within a series of x-ray images.

It remains to be noted that panoramic radiography is particularly suitable for pre-implant diagnosis, particularly in the vertical dimension, because minor setting faults have virtually no influence on the region-dependent vertical magnification factor. Greater setting errors do result in a change of the magnification factors, but they can be kept to a minimum with careful positioning of the patient and the use of appropriately trained operators. When it is considered that a sagittal displacement of the patient backwards in the region of the root tips can enlarge the actual distances by 1.78, it is easy to see that the roots of the adjacent teeth can be slightly damaged by placement of the implant. Therefore, the authors recommend the use of stepped implants that have less of an apical extension where roots are crowded.

References

1. Gómez-Román G, Lukas D, Beniashirili R, Schulte W. Area-dependent Enlargement Ratios of Panoramic Tomography on Orthograde Patient Positioning and Its Significance for Implant Dentistry [Regionenabhängige Vergrößerungsfaktoren der Panoramaschichtaufnahme bei orthograder Patientenpositionierung]. *Int J Oral Maxillofac Implants*, 1999; 14: 248-257.
2. Gómez-Román G, Lukas D, Beniashirili R, Schulte W: Area-Dependent Enlargement Ratios of Panoramic Tomography depending on Asymmetric Incorrect Patient Positioning and Its Significance for Implant Dentistry (Part 2)

[Regionenabhängige Vergrößerungsfaktoren der Panoramaschichtaufnahme in Abhängigkeit von unsymmetrischen Patientenfehlpositionierungen und ihre Bedeutung für die Implantologie (Teil 2)]. *Int.J.Oral Maxillofac Implants* 2003.(in press)

3. Gómez-Román G, Lukas D, Beniashirili R, Schulte W: Area-dependent Enlargement Ratios of Panoramic Tomography Depending on the Symmetrical Incorrect Patient Positioning and Its Significance for Implant Dentistry (Part 3) [Regionenabhängige Vergrößerungsfaktoren der Panoramaschichtaufnahme in Abhängigkeit von symmetrischen Patientenfehlpositionierungen und ihre Bedeutung für die Implantologie (Teil 3)]. *Int.J.Oral Maxillofac Implants* 2003.(in press)
4. Gómez-Román G, d'Hoedt B, Axmann-Krcmar D, Schulte W. Visual-metric measurement of peri implant bone defects on radiographs; A study of reproducibility. *Z Zahnärztl Implantol*, 1996; 12: 104-109.
5. Setz J, Krämer A, Lin W. Vermessen von Orthopantomogrammen in der präimplantären Diagnostik. *Z Zahnärztl Implantol*, 1989; 5: 64-67.
6. Tronje G, Welander U, McDavid WD, Morris CR. Image distortion in rotational panoramic radiography: I. General considerations. *Acta radiol Diagn*, 1981; 22: 295-299.
7. Hayakawa Y, Wakoh M, Fujimori H, Ohta Y, Kuroyanagi K. Morphometric analysis of image distortion with rotational panoramic radiography. *Bull Tokyo Dent Coll*, 1993; 34: 51-58.

Table 1 Extreme horizontal enlargement ratio at the apical end of the implant for various tooth locations. The magnification is shown in bold if there is a significant difference between the incorrect positioned setting and the orthograde positioning. Otherwise the orthograde magnification factors are shown in italics. The reproducibility of the settings at the x-ray apparatus has been selected as the threshold of significance. The average is 9 %. The increase in magnification with the degree of incorrect positioning is indicated with “/”, the decrease with “\”. In part the magnification factors are below 1.0, thus the characteristically magnified panoramic images are reduced.

right	maxilla	lateral	front	front	lateral	left
	mandible	teeth	teeth	teeth	teeth	
Transverse		1.46 /	1.42 /	1.17 \	1.12 \	
sliding to the left		1.42 /	1.45 /	1.16 \	1.01 \	
Sliding sagittal		1.10 \	1.02 \	1.00 \	1.05 \	
forwards		1.06 \	1.01 \	0.99 \	1.02 \	
Sliding sagittal		1.49 /	1.78 /	1.53 /	<i>1.36 /</i>	
backwards		1.36 /	1.63 /	1.51 /	1.33 /	
Tilt to the left		1.16 \	1.17 \	1.46 /	1.38 /	
dorso-ventral		0.97 \	1.12 \	1.43 /	1.38 /	
Rotation to the left		1.53 /	1.53 /	1.08 \	1.06 \	
cranio-caudal		1.60 /	1.56 /	1.05 \	0.98 \	
Tilt transverse		1.17 \	1.19 \	1.15 \	1.12 \	
upwards		1.03 \	1.04 \	0.97 \	0.99 \	
Tilt transverse		1.21 /	1.54 /	1.46 /	1.21 /	
downward		1.38 /	1.65 /	1.56 /	1.33 /	

[<go back>](#)

Figures:

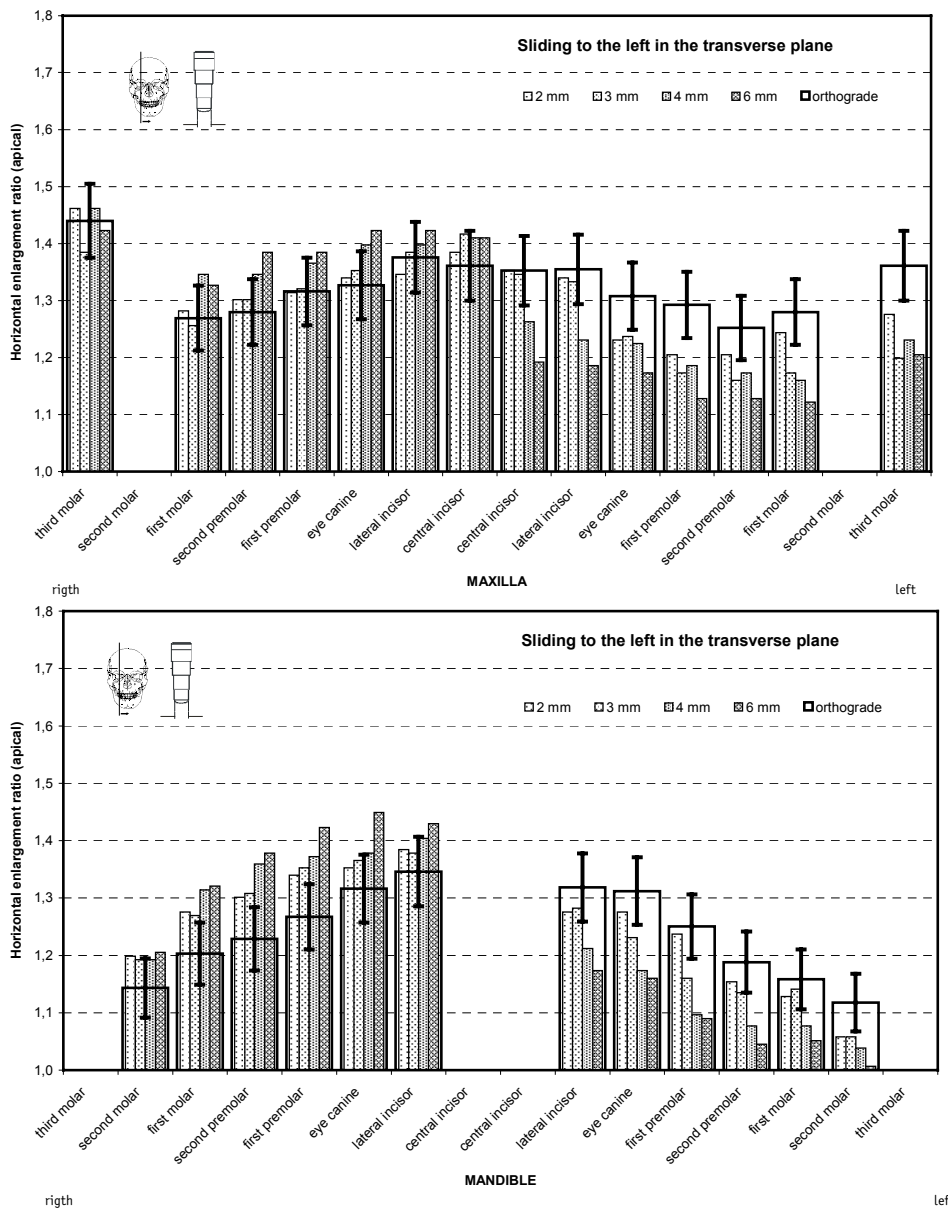


Fig 1 Average horizontal magnification at the apical end of the implant on *sliding to the left in the transverse plane* in the maxilla (top) and [mandible] (bottom). The narrow, increasingly filled pillars show the results with a incorrect position, with increasing degree to the right. The magnification factors with an orthograde setting are shown by the superimposed rectangle, and the reproducibility of the settings at the x-ray apparatus (9%) as vertical lines. [<go back>](#)

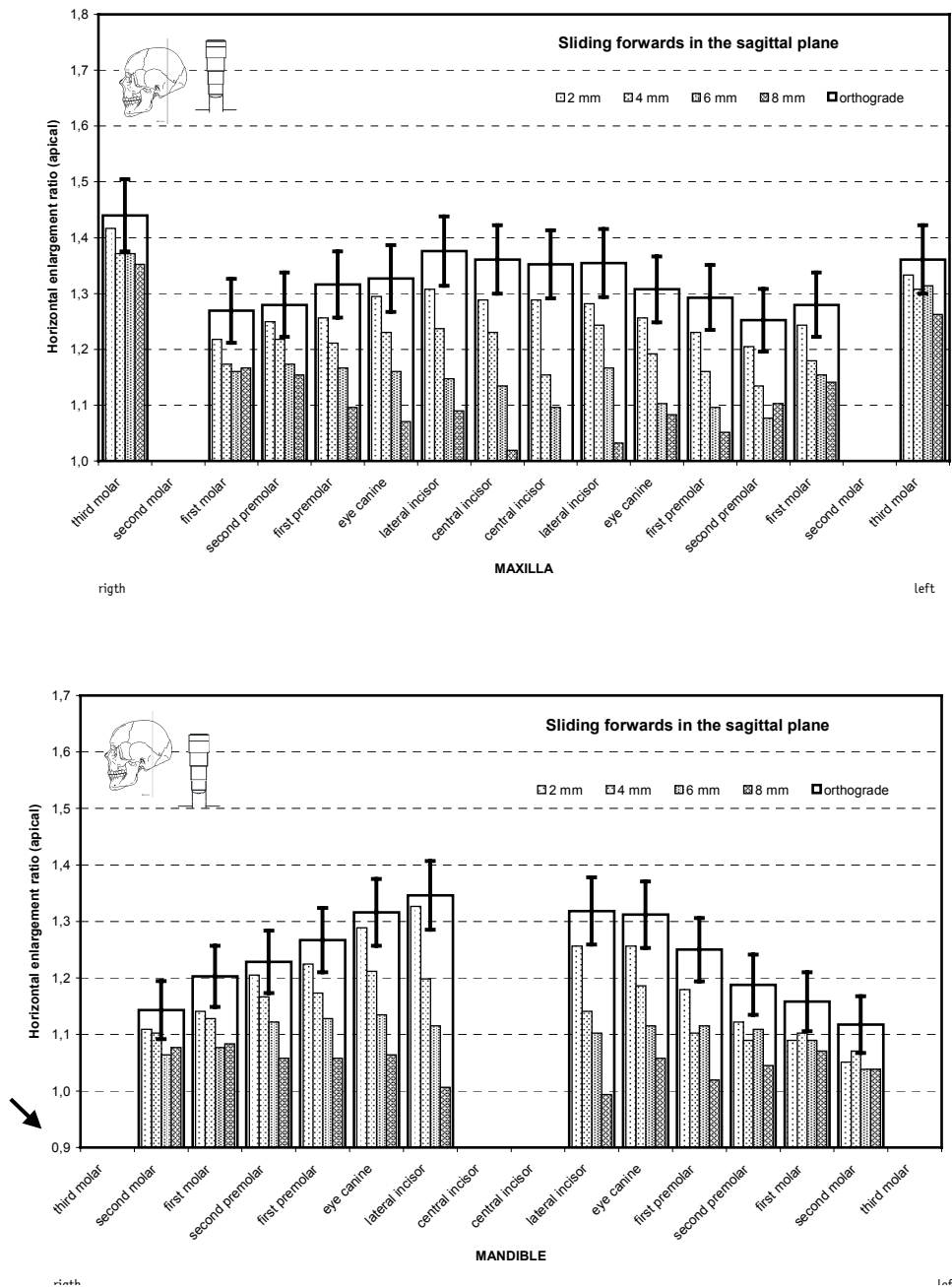


Fig 2 Average horizontal magnification at the apical end of the implant on *sliding forwards in the sagittal plane* in the maxilla (top) and [mandible] (bottom). The narrow, increasingly filled pillars show the results with a incorrect position, with increasing degree to the right. The magnification factors with an orthograde setting are shown by the superimposed rectangle, and the reproducibility of the settings at the x-ray apparatus (9%) as vertical lines.

[<go back>](#)

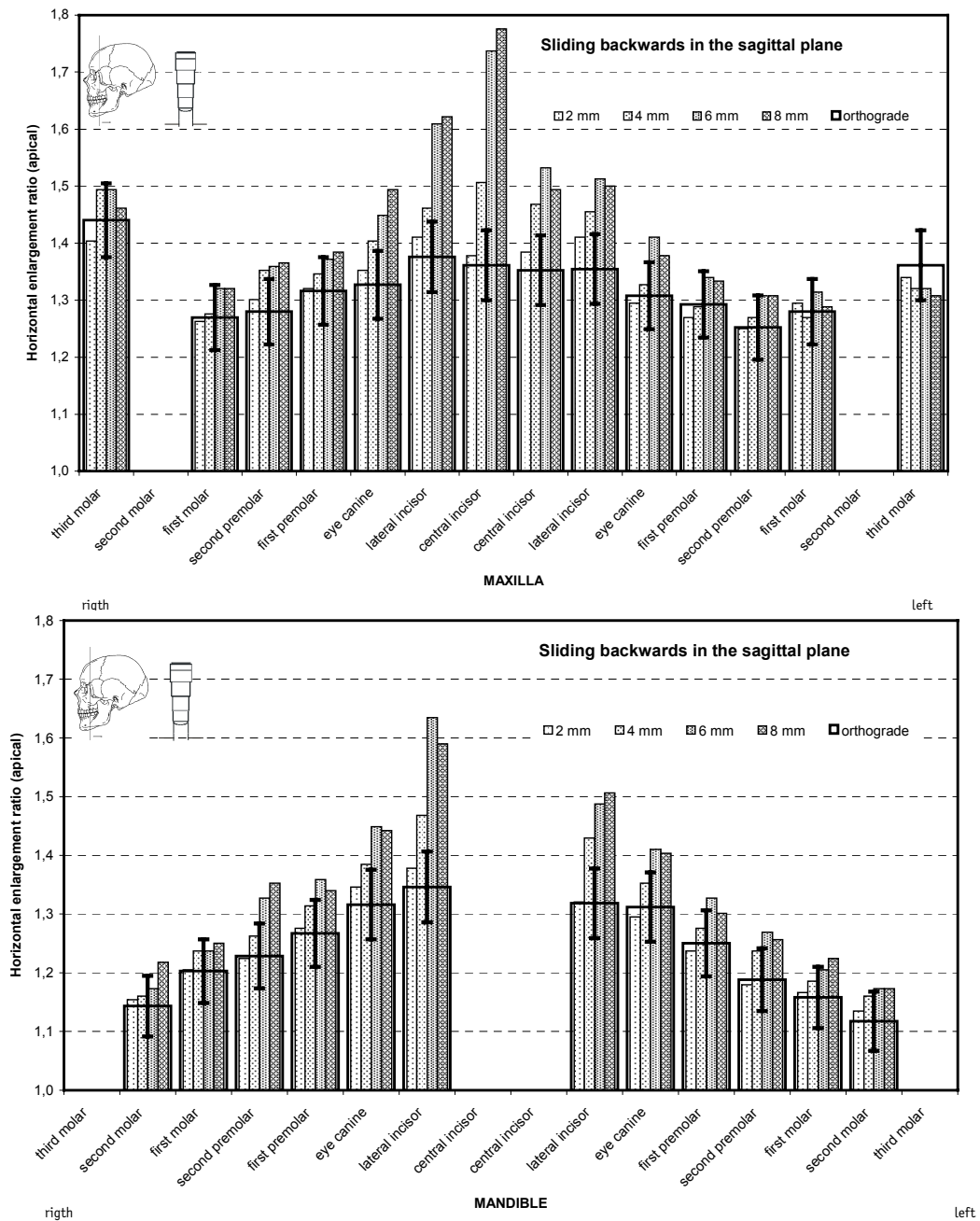


Fig 3 Average horizontal magnification at the apical end of the implant on *sliding backwards in the sagittal plane* in the maxilla (top) and [mandible] (bottom). The narrow, increasingly filled pillars show the results with a incorrect position, with increasing degree to the right. The magnification factors with an orthograde setting are shown by the superimposed rectangle, and the reproducibility of the settings at the x-ray apparatus (9%) as vertical lines.

[<go back>](#)

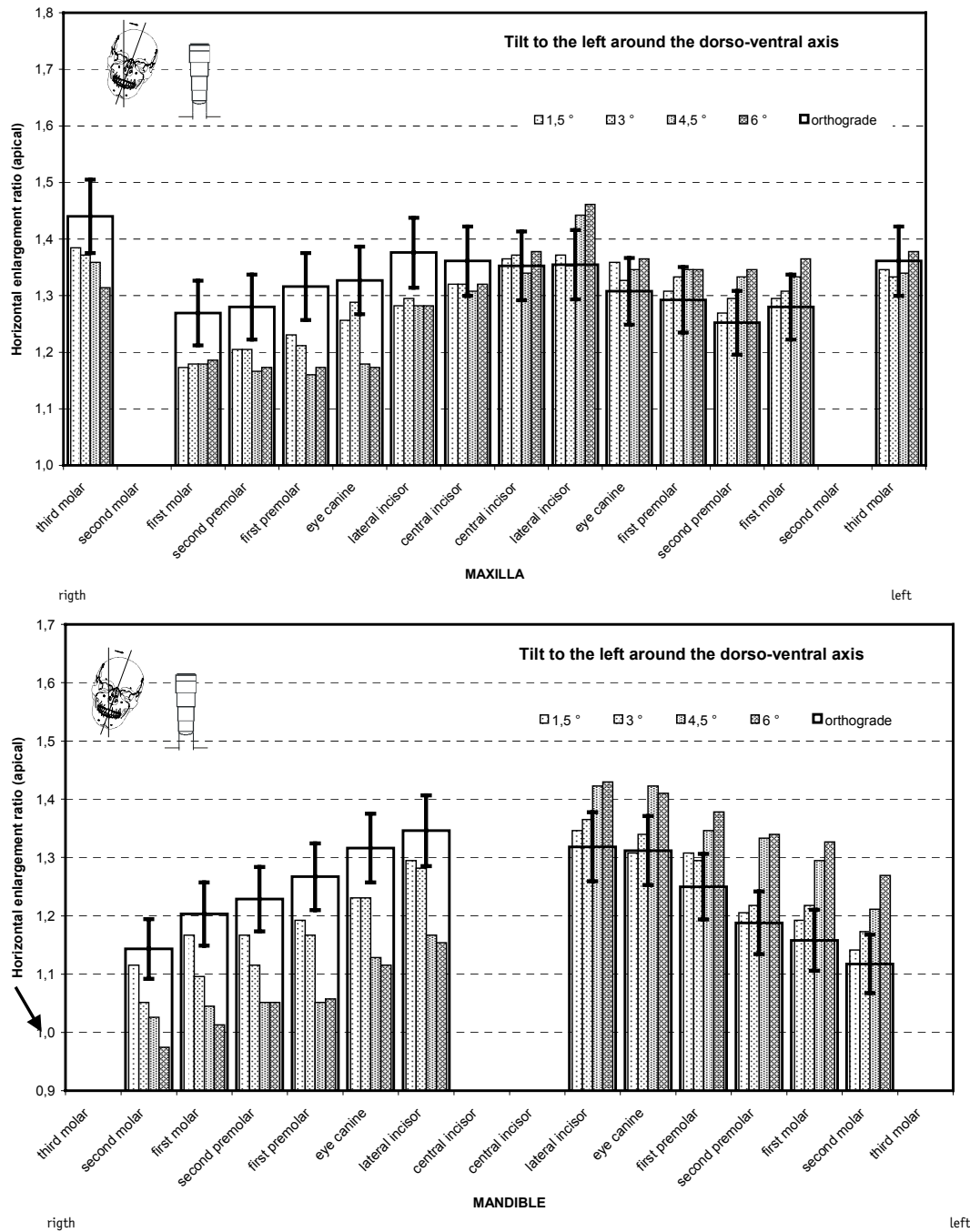


Fig 4 Average horizontal magnification at the apical end of the implant on *tilt to the left around the dorso-ventral axis* in the maxilla (top) and [mandible] (bottom). The narrow, increasingly filled pillars show the results with a incorrect position, with increasing degree to the right. The magnification factors with an orthograde setting are shown by the superimposed rectangle, and the reproducibility of the settings at the x-ray apparatus (9%) as vertical lines.

[<go back>](#)

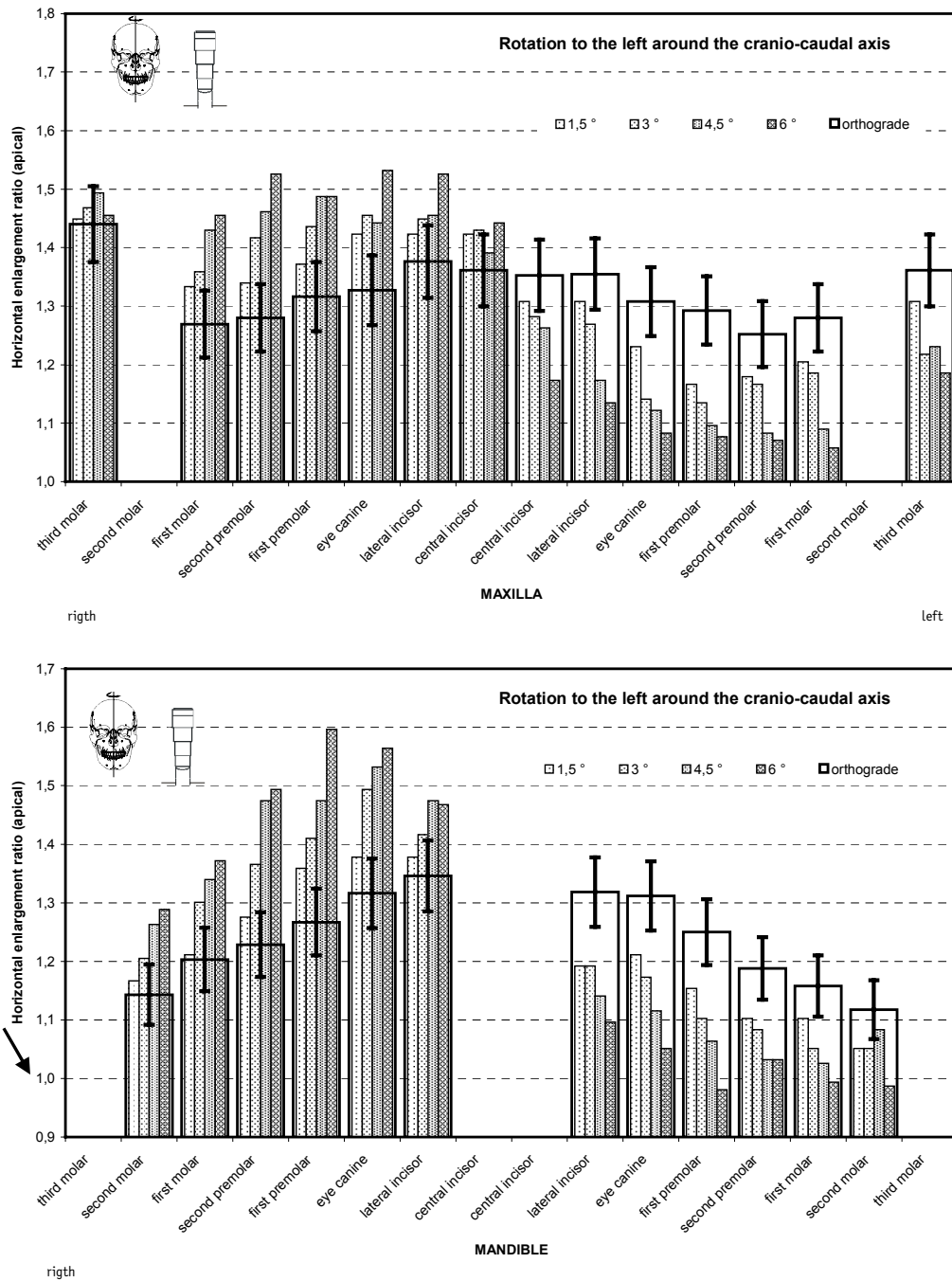


Fig 5 Average horizontal magnification at the apical end of the implant during *rotation to the left around the crano-caudal axis* in the maxilla (top) and (bottom) *s. s.* The narrow, increasingly filled pillars show the results with a incorrect position, to the right with increasing degree. The magnification factors with an orthograde setting are shown by the superimposed rectangle, and the reproducibility of the settings at the x-ray apparatus (9%) as vertical lines.

[<go back>](#)

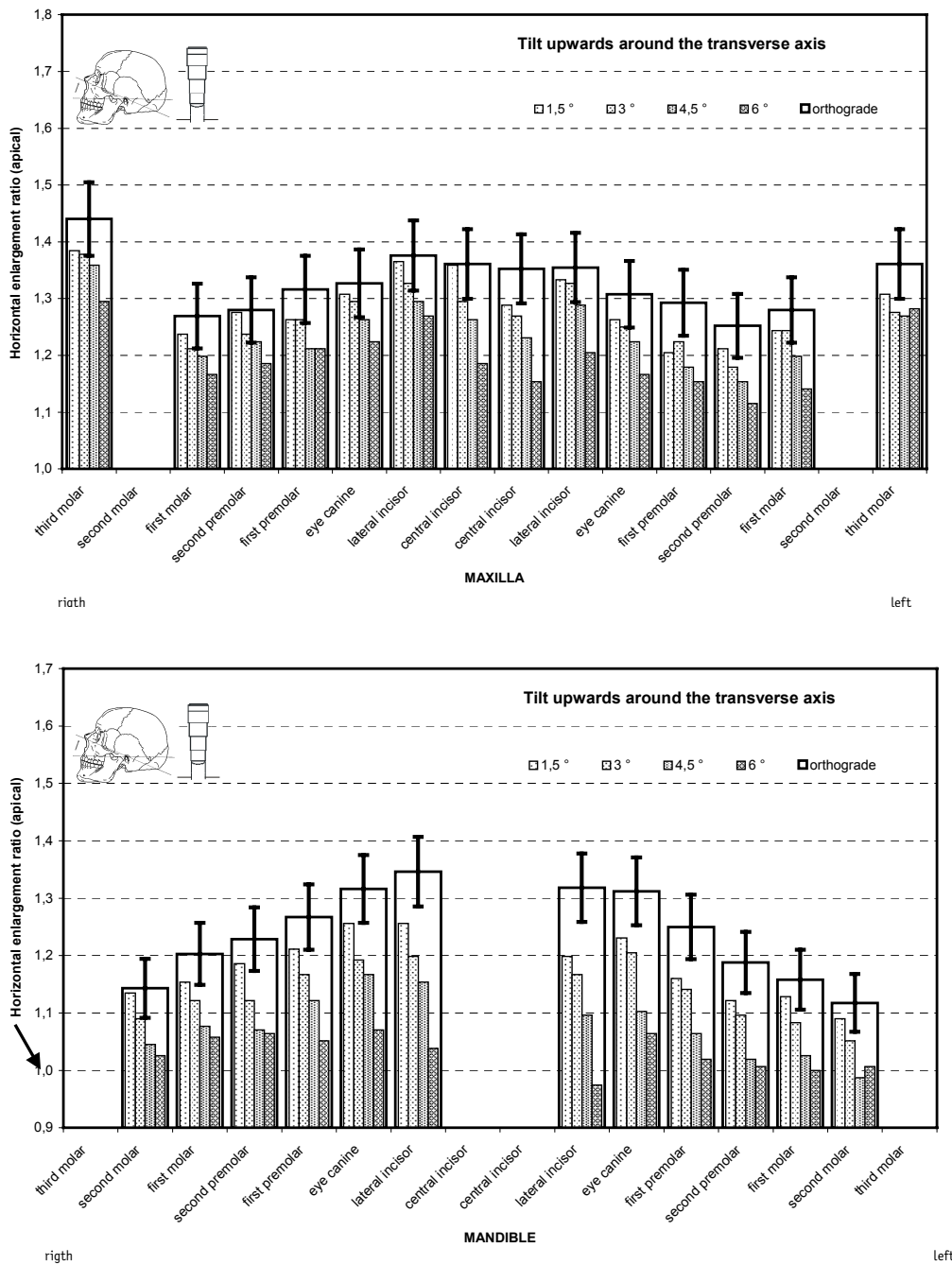


Fig 6 Average horizontal magnification at the apical end of the implant on *tilt upwards around the transverse axis* in the maxilla (top) and (bottom). The narrow, increasingly filled pillars show the results with a incorrect position, with increasing degree to the right. The magnification factors with an orthograde setting are shown by the superimposed rectangle, and the reproducibility of the settings at the x-ray apparatus (9%) as vertical lines. [<go back>](#)

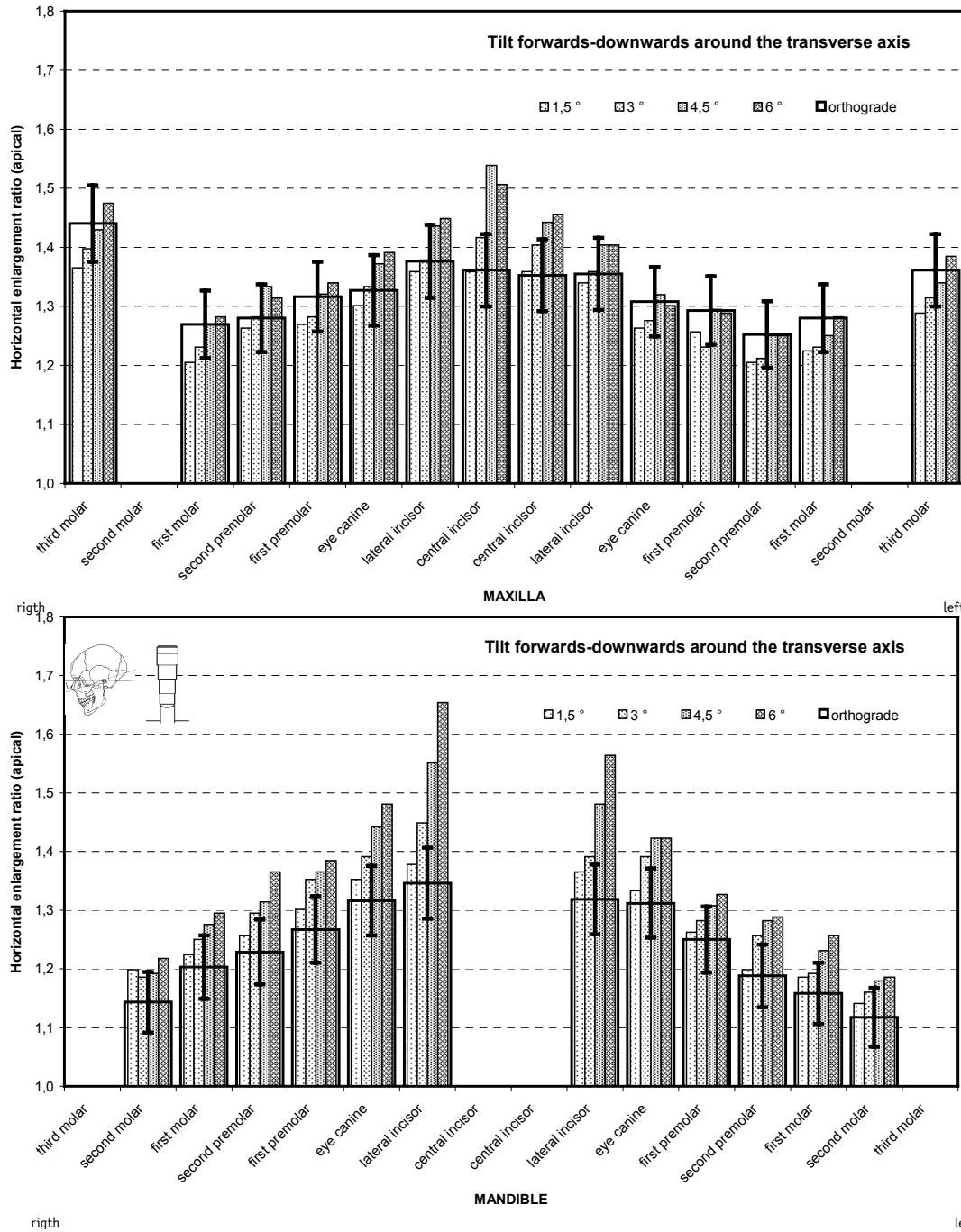


Fig 7 Average horizontal magnification at the apical end of the implant on *tilt forwards-downwards around the transverse axis* in the maxilla (top) and (bottom). The narrow, increasingly filled pillars show the results with a incorrect position, with increasing degree to the right. The magnification factors with an orthograde setting are shown by the superimposed rectangle, and the reproducibility of the settings at the x-ray apparatus (9%) as vertical lines. [<go back>](#)