

Area-Dependent Enlargement Ratios of Panoramic Tomography Depending on Incorrect Patient Positioning and Its Significance for Implant Dentistry

Part 3

Symmetric Patient Positioning

German Gomez-Roman, Dr. med. dent.*, Dieter Lukas, MSc.**, Roman

Beniashvili, Dr. med. dent.***, Willi Schulte, Prof., Dr. med. dent.****

* Associate Professor, Department of Prosthodontics, Dental School, University of Tübingen; and Former head of Collaborative Research Department A7 (Surgery of Dental Implants, Control and Documentation) of Special Research Project SFB175 "Implantology", (German Society of Research),

Osianderstr. 2-8, D-72076 Tübingen, Germany, Fax No. ++49 7071 293982.

**Research Fellow, former Clinic of Oral and Maxillofacial Surgery, Dental School, Eberhard-Karl-University, Osianderstr. 2-8, D-72076 Tübingen, Germany, e-mail: drmed_lukas@web.de, <http://www.periotest.de/lukas/>

*** Dentist, former Department of Oral Surgery and Periodontology, Dental School, University of Tübingen, Osianderstr. 2-8, D-72076 Tübingen, Germany

****Professor Emeritus, Department of Oral Surgery and Periodontology, Dental School, University of Tübingen; and Former Speaker of Special Research Project SFB175 "Implantology" (German Society of Research), Osianderstr. 2-8, D-72076 Tübingen, Germany

Reprint request: Priv.-Doz. Dr. G. Gomez-Roman, Poliklinik für Zahnärztliche Prothetik und Propädeutik, Universitätsklinikum Tübingen, Osianderstrasse 2-8, D-72076 Tübingen, Germany, Fax: +49-7071-293 982, e-mail: german.gomez-roman@med.uni-tuebingen.de

Area-dependent enlargement ratios of panoramic tomography on the symmetrical incorrect patient positioning and its significance for implant dentistry (Part 3)

Abstract

Objective: This study investigates the behavior of the vertical and horizontal magnification factors on panoramic radiography images with symmetrical incorrect patient positioning. See the previously published parts 1 and 2 for optimum positioning and [asymmetrical](#) incorrect positioning. **Method and materials:** Various degrees of symmetrical incorrect positioning of a macerated skull were set with a sliding and tilting table on the skull retainer. **Results:** Incorrect positioning of the skull influenced the vertical and horizontal magnification factors to different degrees. The strongest effects on the vertical magnification factor were observed during sliding backwards in the sagittal plane. The bone volume available for implant placement was underestimated in all regions of the jaw. The horizontal magnification factor was influenced significantly more by the incorrect positioning. **Conclusion:** When the results for symmetrical incorrect patient positioning and the results for asymmetrical patient positioning are considered, the panoramic radiography technique is shown to be a suitable procedure for both pre-implant diagnostics and also for monitoring the procedure and the success of the procedure. Because the patient positioning in the horizontal dimension has a great influence on the magnification factors, particularly in the interforaminal region, imaging of dense metallic structures of known dimensions, such as 5-mm balls, can also continue to be recommended.

Key words: area-dependent; imaging technique with incorrect positioning; Frialit-2; enlargement, dental implantology; panoramic radiography; radiographic measuring

Introduction

The significance of panoramic radiography for pre-implant diagnostics has been described in detail for orthograde positioning in the first section of this article ¹. The [second part](#) of this study presented the magnification and distortion caused by

incorrect patient positioning and our results for asymmetrical incorrect positioning². This third part presents the results for symmetrical incorrect positioning.

Material and Methods

The examinations were conducted on an edentulous, macerated skull with 26 Frialit™-2 stepped cylinder implants. The full procedure including the x-ray technique in the optimum orthograde setting has been described in detail in the first part of this study¹.

The macerated skull was fixed on a plane or axis that deviated from its optimum orthograde position and x-rayed to examine the influence of the incorrect positioning on the distortion and magnification factor. The following incorrect settings were selected (compare the schematic views in the diagrams at top left):

Sliding towards anterior and posterior in the median sagittal space plane: The complete anchoring of the skull was moved 2 mm, 3 mm, 4 mm and 6 mm to anterior or posterior along a slot in the skull holder. The exact course of the milled slot parallel to the median sagittal plane of the skull and with reference to the beam path was observed.

Tilt up or down around the transverse space axis: The skull was tilted by 1.5, 3.0, 4.5 and 6.0 degrees at the base joint. To compensate for the excessively large distance of the occipital condyle to the base joint, the skull was moved in the posterior direction when tilted up and in the anterior direction when tilted down, and the x-ray apparatus height setting was matched to the position of the skull, as described in detail in part 2.

A total of four different incorrect positions were studied and each of the four was classified into four subclasses according to the degree of the incorrect setting. Six images were made of every subclass, which combined with the asymmetrical incorrect positioning described in part 2 made a total of 168 incorrectly positioned panoramic radiography images.

Cephalometric analysis, measurement of the implants and the statistical methods used were described in detail in the first part of this study¹.

Results

The magnification factors of the incorrectly positioned panoramic radiography images are based on the results with orthograde position and placed in relation to the reproducibility of the settings at the x-ray unit³. All magnification factors with incorrect positioning were calculated from six individual values for every one of the four degrees, and with orthograde positioning from 18 individual values. The horizontal magnification was calculated at the coronal implant step. The report on the magnification factors at the apical implant step, 11 mm outside the occlusion plane, can be found in an [appendix](#) on-line⁴.

Sliding forward in the sagittal plane. Both jaws showed a tendency to reduction, becoming more reduced with increasing incorrect positioning ([Fig. 1](#)). In the maxilla this reduction was significant from a sliding of 8 mm, in part from 6 mm, in the mandible only in the frontal region and only at 8 mm.

The *horizontal* magnification factor at the coronal implant step was reduced in all implant regions ([Fig. 2](#)). This change increased with increasing incorrect positioning. This effect was particularly marked in the anterior jaw sections. The reduction was significant except for the third right molar. In part magnification factors of only 0.96 were reached, which in the enlarged view typical for panoramic radiography images became a reduction. In comparison with the vertical magnification factors, incorrect positioning shows a significantly greater influence on the horizontal magnification factor. This was observed with all subsequent incorrect positions.

Sliding backwards in the sagittal plane. The changes in the *vertical* magnification factors are shown in [Fig. 3](#). The increase in the magnification factor with increasing degree of incorrect positioning was clear in both jaws with this incorrect positioning. In the maxilla this change was significant from 6 mm sliding compared to the orthograde positioning, from 4 mm with the left molars and 2 mm with the two third molars; in the mandible with the premolars from 2 mm and otherwise from 4 mm.

The *horizontal* magnification factors increased significantly with increasing incorrect positioning in both jaws ([Fig. 4](#)). This tendency was most clearly observed in

the anterior jaw sections, where the magnification of up to 1.7 significantly exceeded that with orthograde positioning, while the change in the posterior jaw section was not significant.

Tilt upwards around the transverse axis. The changes in the *vertical* magnification factors are shown in Fig. 5. The magnification factors are reduced uniformly in all regions.

In the *horizontal* direction all four quadrants were reproduced in reduced form (Fig. 6). The horizontal magnification factors went down with increasing tilt. These changes were significant.

Tilt downwards around the transverse axis. The changes of the *vertical* magnification factor are shown in Fig. 7. All regions experienced a tendency to the equivalent increase of the magnification factor with increasing deviation from the orthograde positioning. At a tilt of 1.5° the magnification was reduced in comparison to the orthograde positioning.

All quadrants were also behaved equivalent in the *horizontal* magnification. With increasing incorrect positioning the horizontal magnification factors grew, but significantly only in the front (Fig. 8).

Discussion

These results demonstrate that on *sliding in the sagittal plane* symmetrical changes occur in both maxilla and mandible. The horizontal magnification factors depend on the incorrect positioning significantly above that with vertical magnification. This is particularly marked in the region of the front teeth and the first premolars. It is possible that the oro-vestibular implant position and inclination is responsible for the different behavior of the magnification factors, because the projection angle of the implants changes by the negative curve of the central beam ($6^\circ - 8^\circ$ caudal) depending on their projection with the various repositioning. The study of the horizontal magnification factors also indicated similar tendencies, but in a more marked form, on sliding in the sagittal plane. The horizontal magnification factors increased much more strongly on sliding backwards than they fell on sliding forwards. Results of previous studies also demonstrated the same effect, according to which

the horizontal magnification factor of those objects repositioned to the center of rotational movement from the sharply imaged slice are changed more strongly than with the repositioning of the same objects in the direction of the film by the same distance^{5,6}. The results of studies in which the influence of the restricted width of the sharply imaged slice in this regions on the magnification factor confirm that the most extreme variations of the magnification factor were detected in the anterior region of the jaw^{7,8}.

It is significant for implant dentistry that the view of the implants is reduced vertically and horizontally in comparison to the orthograde setting on sliding forwards and magnified on sliding backwards. The bone volume will be underestimated or overestimated in a panoramic radiography image incorrectly positioned forwards and particularly backwards if auxiliary objects are not used to calculate the magnification factor. An overestimate of this magnitude would have particularly serious consequences.

Symmetrical changes in the vertical and horizontal dimension were also observed in both halves of the maxilla and mandible on *tilt up and down*. The change in the horizontal magnification factors greatly exceeded those in the vertical direction, indicating serious distortion of the implants on the panoramic radiography image. The change of the image scale with these incorrect positions can be explained by a repositioning from the sharply imaged plane in the direction of the center of rotation or the film, as noted by Tronje et al.⁹ and Hayakawa et al.⁵. The change in the mesio-distal implant inclination caused by the incorrect positioning must also play a role. Increasing tilt upwards at the transverse axis causes a reduction in all regions of the maxilla compared to an orthograde image. The available vertical bone volume is underestimated accordingly, particularly in the interforaminal region. In contrast, implants are shown magnified when tilted downwards. Accordingly the vertical bone volume is overestimated.

For *pre-implant* diagnosis it can be concluded for both symmetrical and asymmetrical (part 2) incorrect positioning that noticeably large changes of the vertical magnification factors, which are significant for the implant dentist, are observed primarily on rotation around the cranio-caudal axis and sliding backwards in

the sagittal plane. The isolated incorrect positions, which are sliding in the transverse plane, tilt at the dorso-ventral axis and rotation at the cranio-caudal axis, can be visually identified with the aid of selected assessment criteria and by measurement of the appropriate anatomical distances. So magnification factors calculated during pre-implant planning can be used with all *asymmetrical* incorrect positions¹⁰. The results for the vertical magnification can also be transferred without restrictions to implants that are longer than those we used, because the size of the object does not play an important role, as demonstrated by Hayakawa et al.⁵.

A safety distance of 1 mm to the endangered anatomical structures must be observed with all *symmetrical* incorrect positions. The region-dependent magnification factors that we calculated also show that comparison bodies (see below) are essential to ensure sufficient inter-implant distance. In the interforaminal region in the mandible, which is increasingly important to implant dentistry, this study has calculated the maximum deviations with all examined horizontal incorrect positions. The attention to these matters can improve implant planning.

Transparent templates with implant outline drawings, which only take an average magnification factor into account, are used in the clinical routine. According to previous studies, an overestimation of 2 – 6 % of the available bone volume must be assumed for incorrectly positioned patients¹¹. This study shows that incorrect positioning can not only result in overestimation of the available bone volume but also to underestimation. For this reason different procedures to improve calculation of the image scale are required, for example ball measurement procedures fabricated before implant with a sufficient number of balls for more precise calculation of the region-dependent magnification factor and to determine the incorrect position.

It remains to be noted that panoramic radiography is particularly suitable for pre-implant diagnosis, particularly in the vertical dimension, because minor setting faults have virtually no influence on the region-dependent vertical magnification factor. Greater setting faults do result in a change of the magnification factors, but they can be kept to a minimum with careful positioning of the patient and the use of appropriately trained operators.

References

1. Gómez-Román G, Lukas D, Beniashirili R, Schulte W. Area-dependent Enlargement Ratios of Panoramic Tomography on Orthograde Patient Positioning and Its Significance for Implant Dentistry. *Int J Oral Maxillofac Implants*, 1999; 14: 248-257.
2. Gómez-Román G, Lukas D, Beniashirili R, Schulte W: Area-Dependent Enlargement Ratios of Panoramic Tomography depending on Asymmetric Incorrect Patient Positioning and Its Significance for Implant Dentistry (Part 2). Online. <http://w210.ub.uni-tuebingen.de/dbt/volltexte/2003/681pdf/2unsymmetrisch.pdf>. **2003-I-21**
3. Gómez-Román G, d'Hoedt B, Axmann-Krcmar D, Schulte W. Visual-metric measurement of peri implant bone defects on radiographs; A study of reproducibility. *Z Zahnärztl Implantol*, 1996; 12: 104-109.
4. Gómez-Román, G., Lukas, D., Beniashirili, R., and Schulte, W. Area-dependent enlargement ratios of panoramic tomography depending on incorrect patient positioning and its significance for implant dentistry; Appendix: Horizontal magnification factors at the apical implant step. Online. <http://w210.ub.uni-tuebingen.de/dbt/volltexte/2003/681/pdf/5apic.pdf>. **2003-I-21**
5. Hayakawa Y, Wakoh M, Fujimori H, Ohta Y, Kuroyanagi K. Morphometric analysis of image distortion with rotational panoramic radiography. *Bull Tokyo Dent Coll*, 1993; 34: 51-58.
6. Welander U. A mathematical model of narrow beam rotation methods. *Acta radiol Diagn*, 1974; 15: 305-317.
7. Sjöblom A, Welander U. Position, form and thickness of the image layer in narrow beam rotation radiography. *Acta radiol Diagn*, 1978; 19: 697-704.
8. Welander U. Layer formation in narrow beam rotation radiography. *Acta radiol Diagn*, 1975; 16: 529-540.
9. Tronje G, Welander U, McDavid WD, Morris CR. Image distortion in rotational panoramic radiography: I. General considerations. *Acta radiol Diagn*, 1981; 22: 295-299.
10. Windisch, S. Die visuelle Beurteilung von Panoramiaschichtaufnahmen-Rückschlüsse auf Felpositionierung und ihre Bedeutung für die Implantologie [Visual assessment of panoramic radiography images – conclusions regarding incorrect positioning the significance for implant dentistry]. Thesis Diss med dent, Univ Tuebingen. 1997.
11. Szabo G, Keck B, d'Hoedt B. Präimplantologische Diagnostik mit individuellen Röntgenschablonen im Orthopantomogramm. *Z Zahnärztl Implantol*, 1991; VII: 33-36.

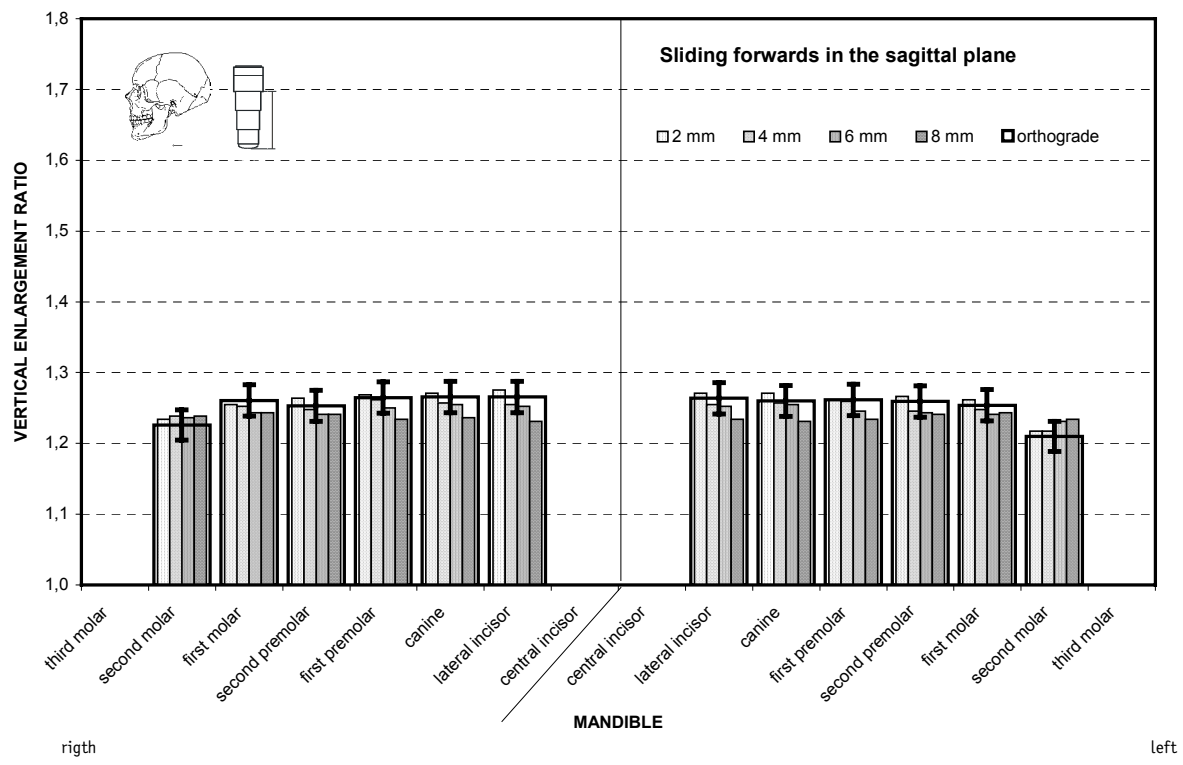
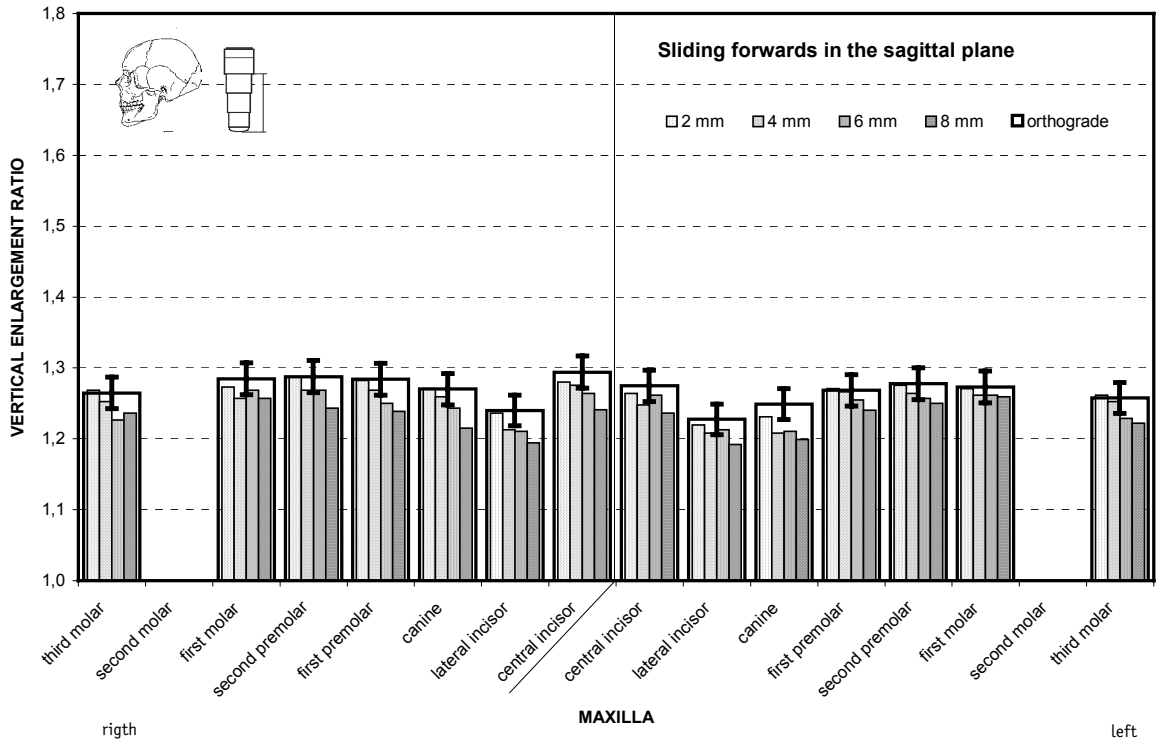


Fig. 1 Average vertical magnification on *sliding forwards in the sagittal plane*. The narrow, increasingly filled pillars show the results with an incorrect position, increasing in degree to the right. The magnification factors with an orthograde setting are shown by the superimposed rectangle, and the reproducibility of the settings at the x-ray apparatus (3.5%) as vertical bars.

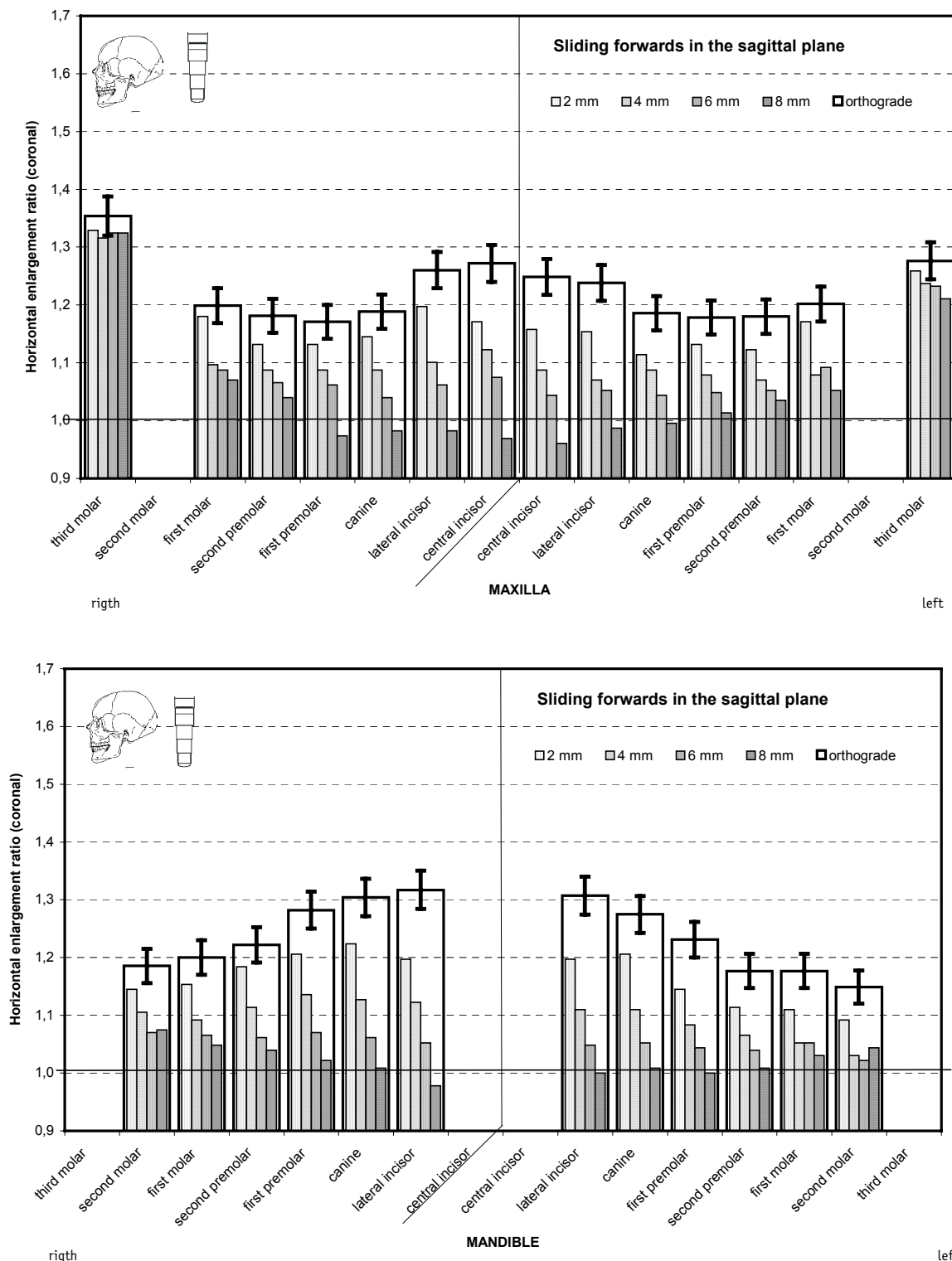


Fig. 2 Average horizontal magnification at the coronal end of the implant on *sliding forwards in the sagittal plane*. The display corresponds to Fig. 1. The reproducibility of the settings at the x-ray apparatus is 5%. In part the magnification characteristic with panoramic radiography images reverses to become a reduction (note the 1.0 line).

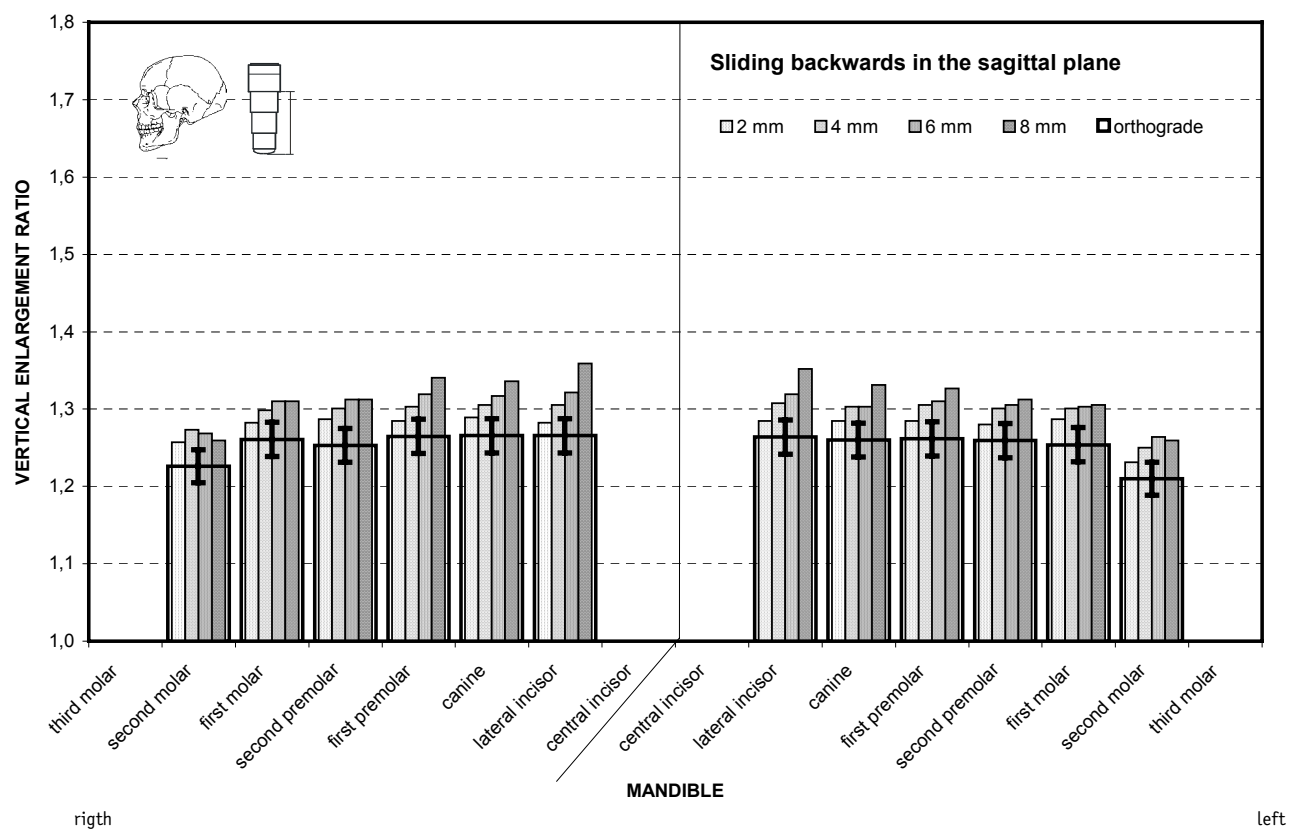
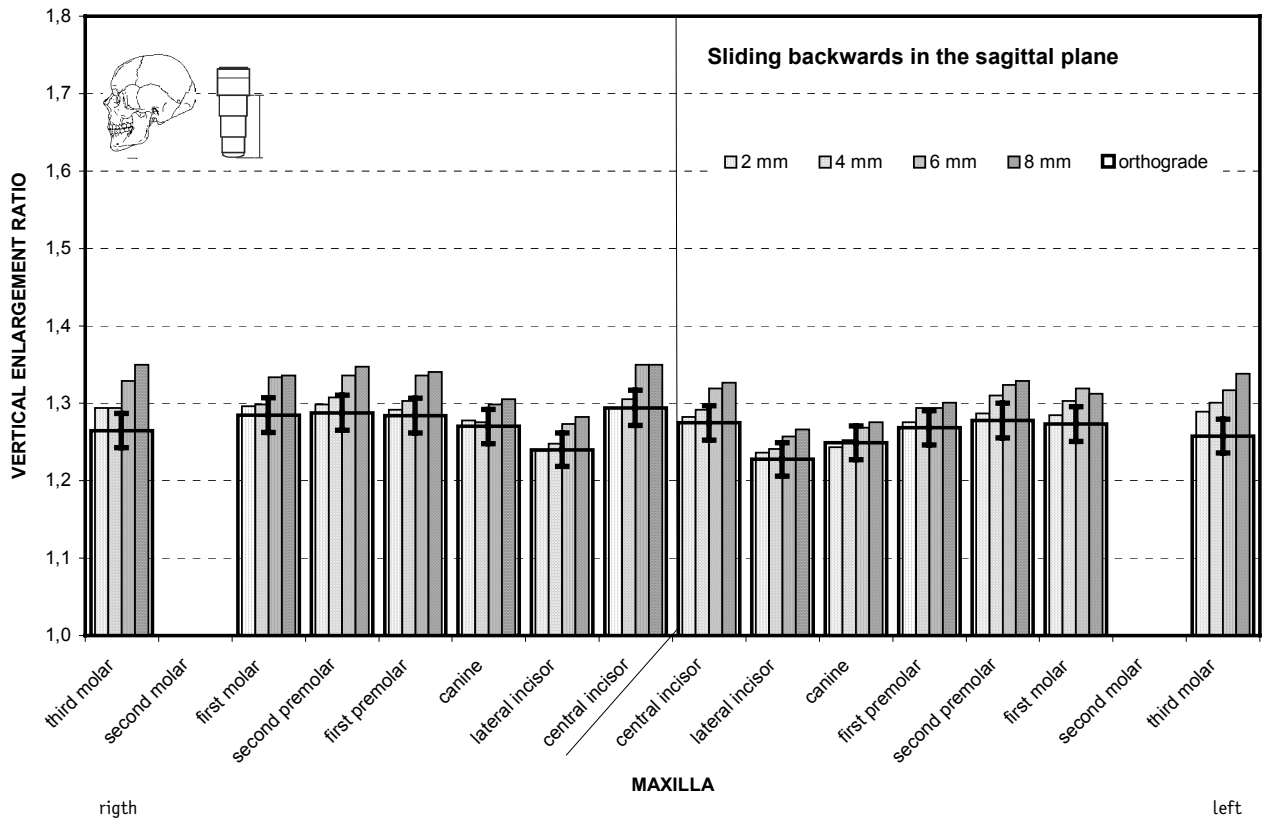


Fig. 3 Average vertical magnification on *sliding backwards in the sagittal plane*.

The narrow, increasingly filled pillars show the results with an incorrect position, increasing in degree to the right. The magnification factors with an orthograde setting are shown by the superimposed rectangle, and the reproducibility of the settings at the x-ray apparatus (3.5%) as vertical bars.

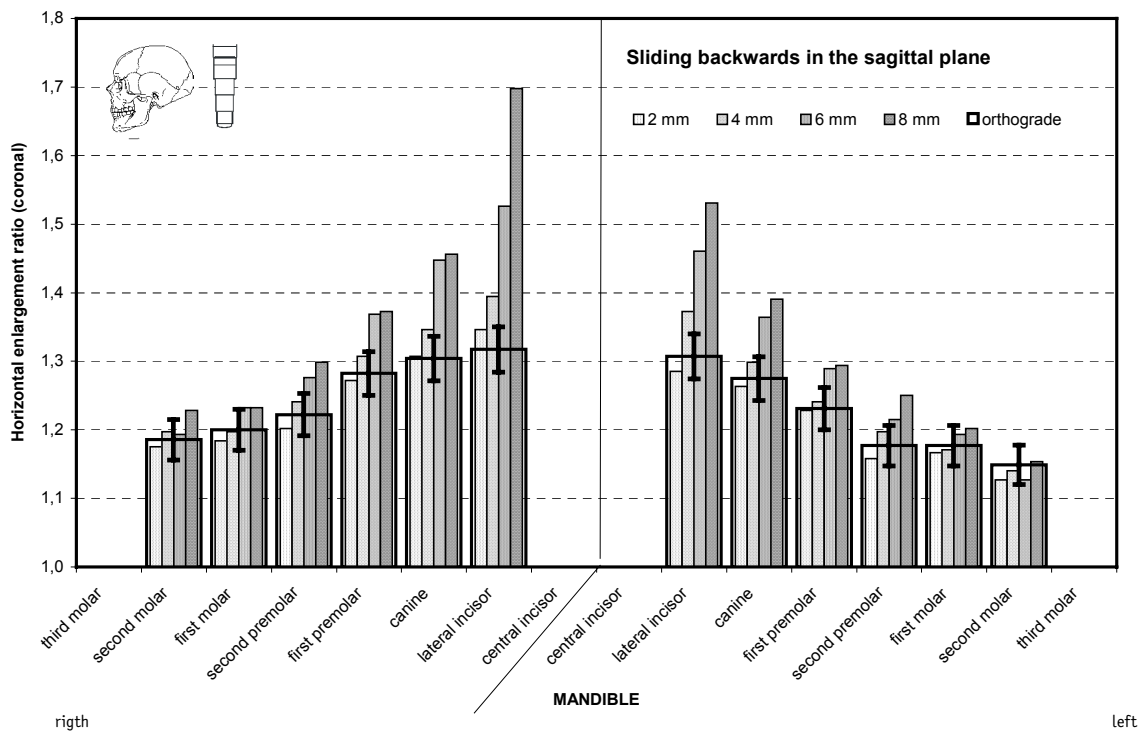
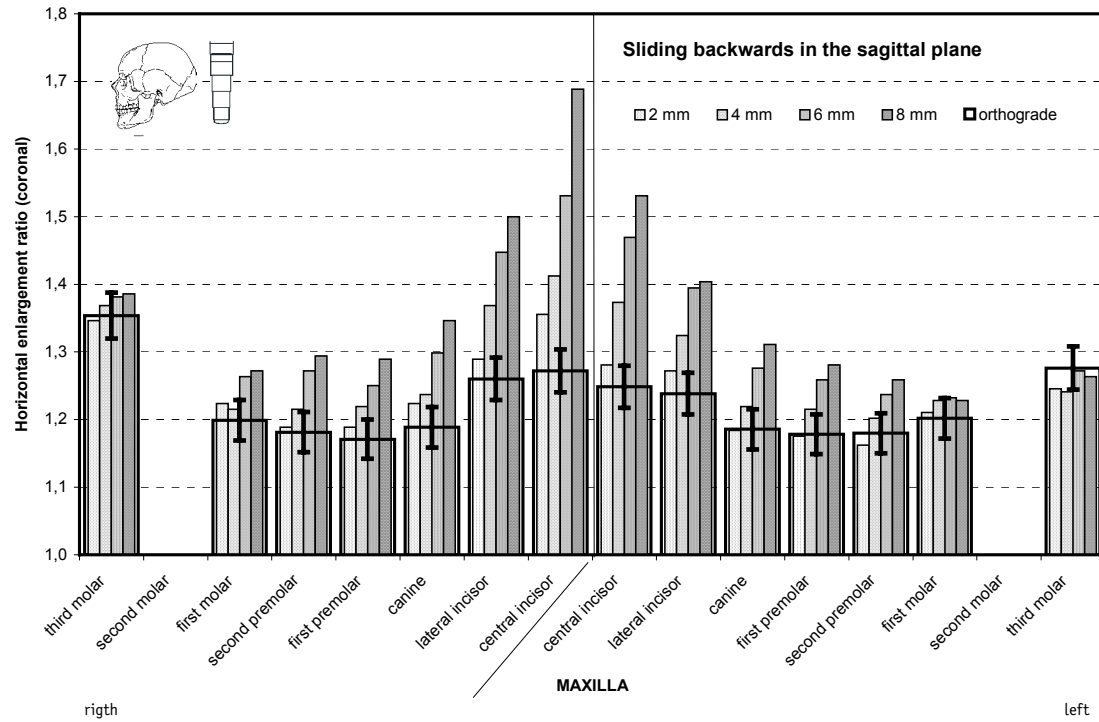


Fig. 4 Average horizontal magnification at the coronal end of the implant on *sliding backwards in the sagittal plane*. The display corresponds to Fig. 3. The reproducibility of the settings at the x-ray apparatus is 5%.

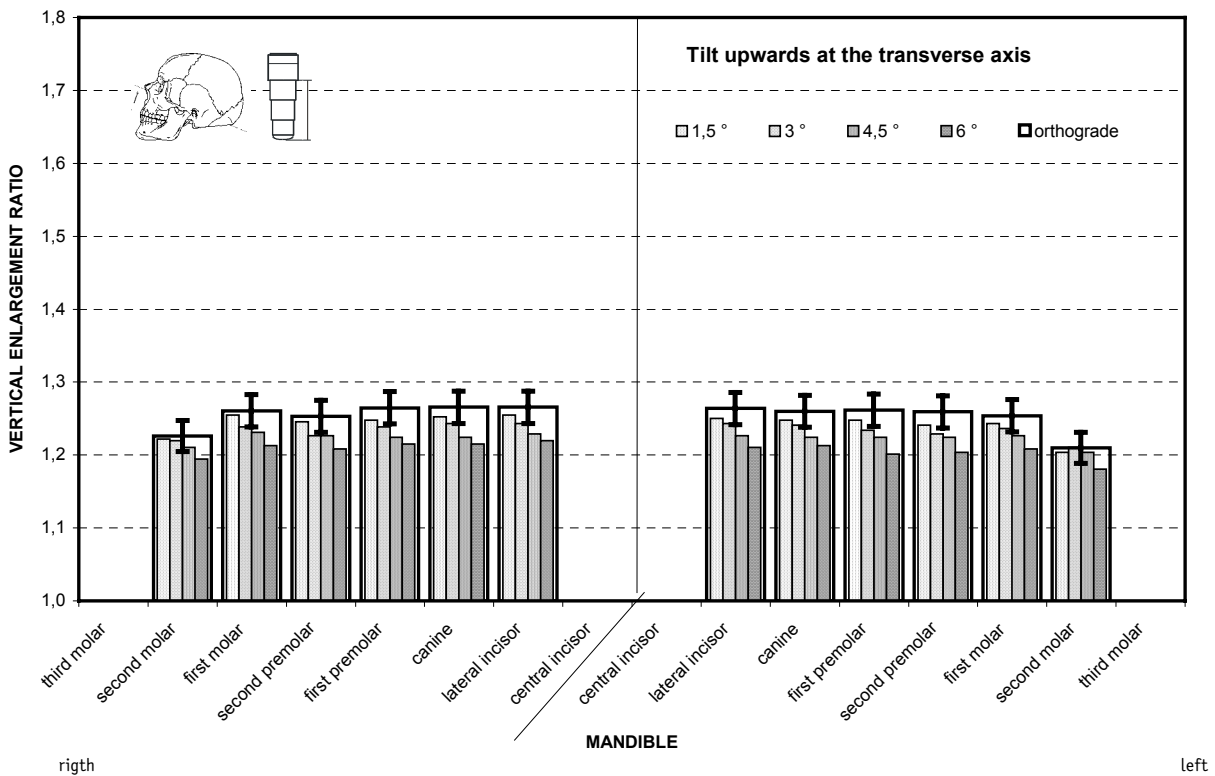
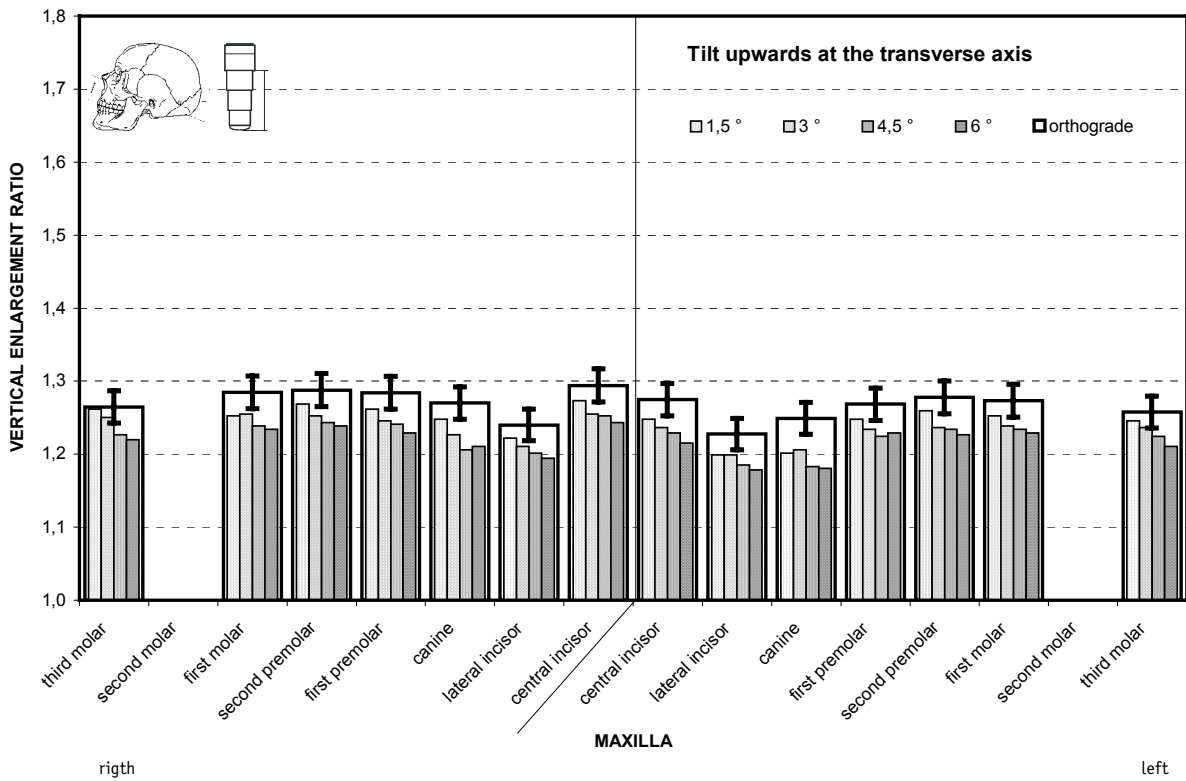


Fig. 5 Average vertical magnification on *tilt upwards at the transverse axis*. The narrow, increasingly filled pillars show the results with an incorrect position, increasing in degree to the right. The magnification factors with an orthograde setting are shown by the superimposed rectangle, and the reproducibility of the settings at the x-ray apparatus (3.5%) as vertical bars.

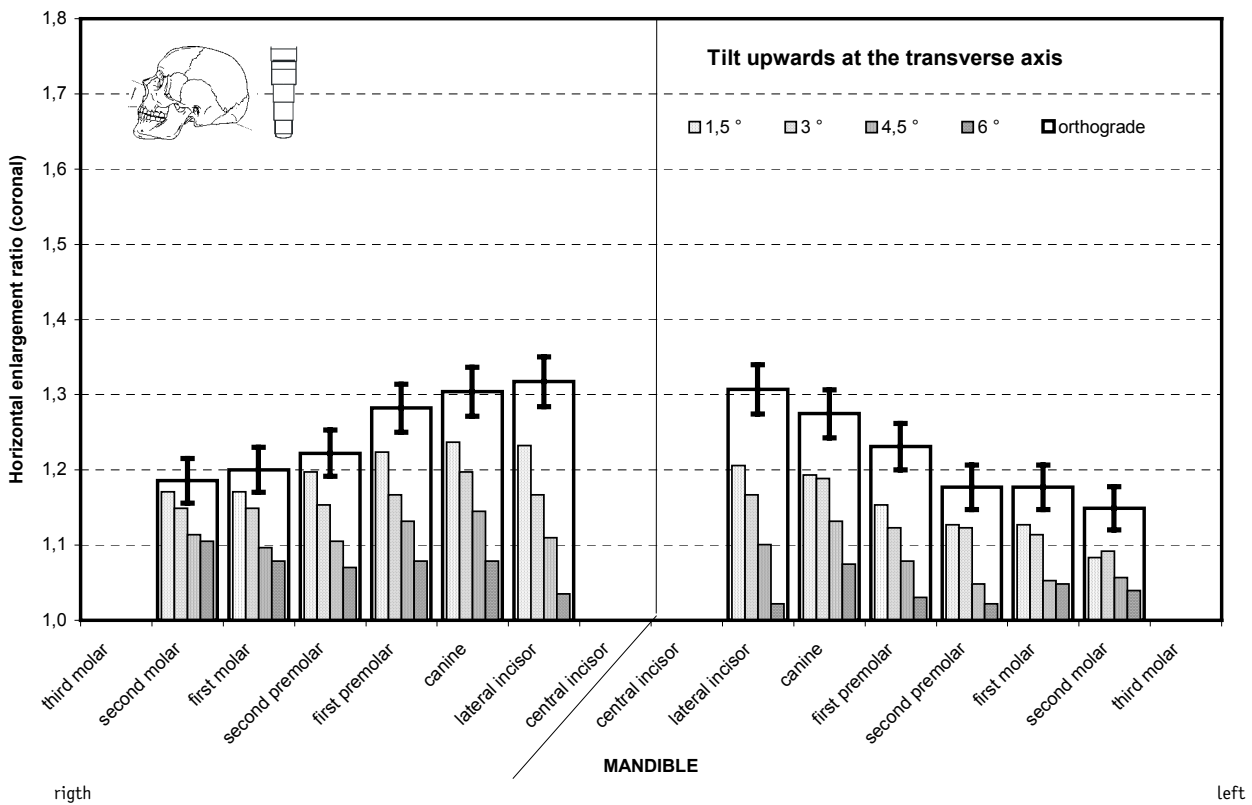
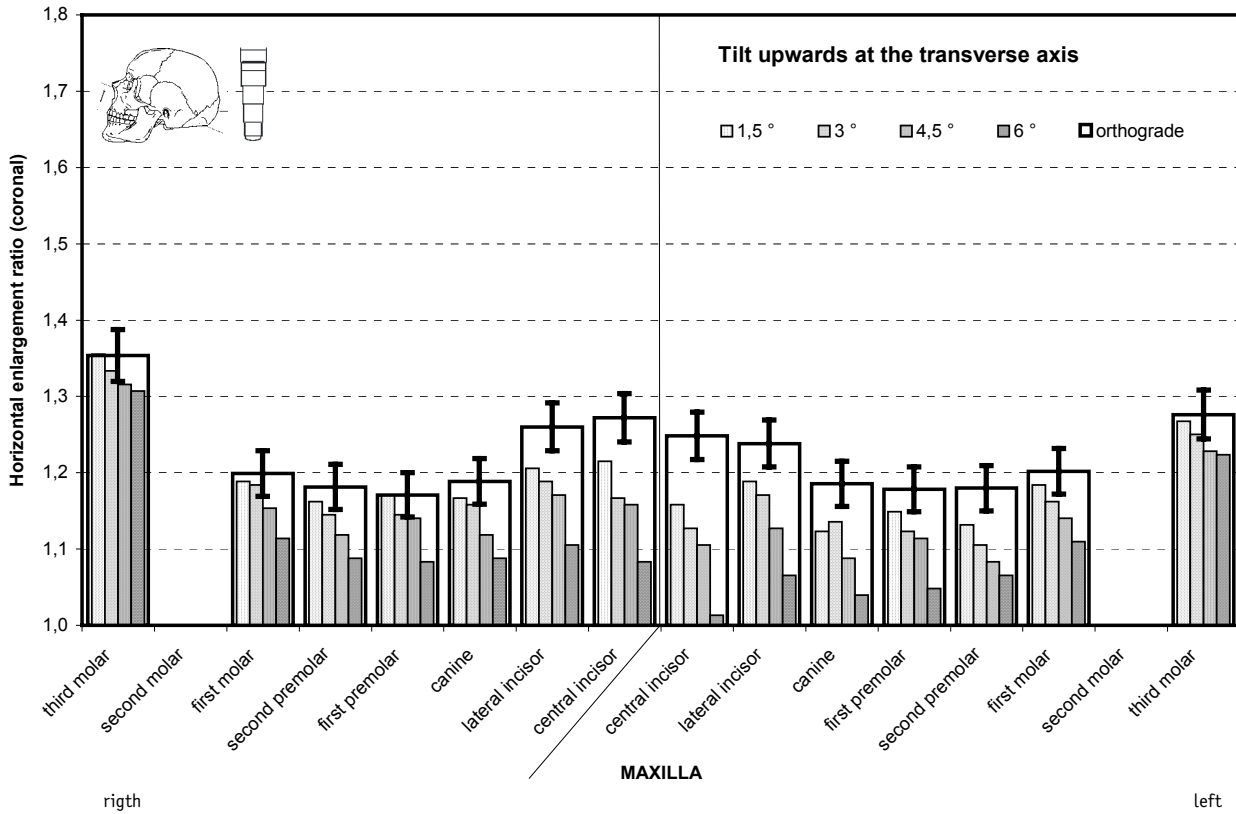


Fig. 6 Average horizontal magnification at the coronal end of the implant on *tilt upwards at the transverse axis*. The display corresponds to Fig. 5. The reproducibility of the settings at the x-ray apparatus is 5%.

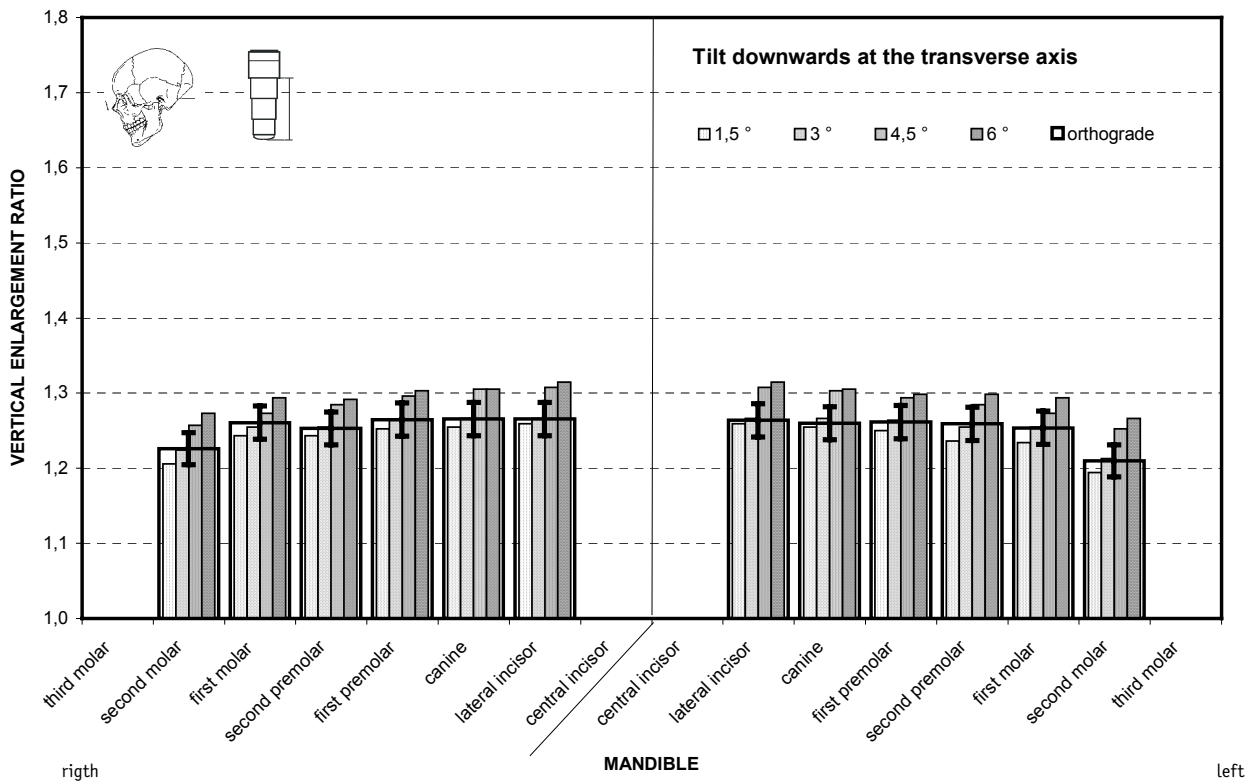
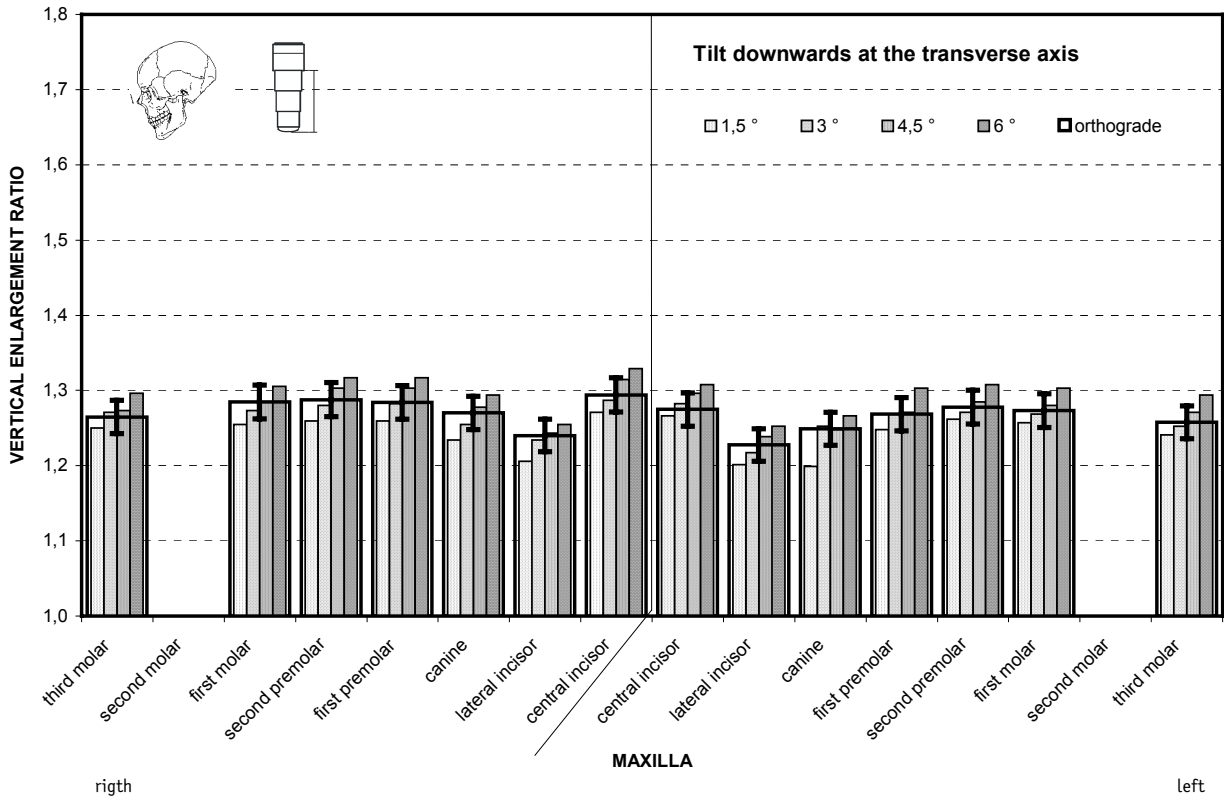


Fig. 7 Average vertical magnification on *tilt downwards at the transverse axis*. The narrow, increasingly filled pillars show the results with an incorrect position, increasing in degree to the right. The magnification factors with an orthograde setting are shown by the superimposed rectangle, and the reproducibility of the settings at the x-ray apparatus (3.5%) as vertical bars.

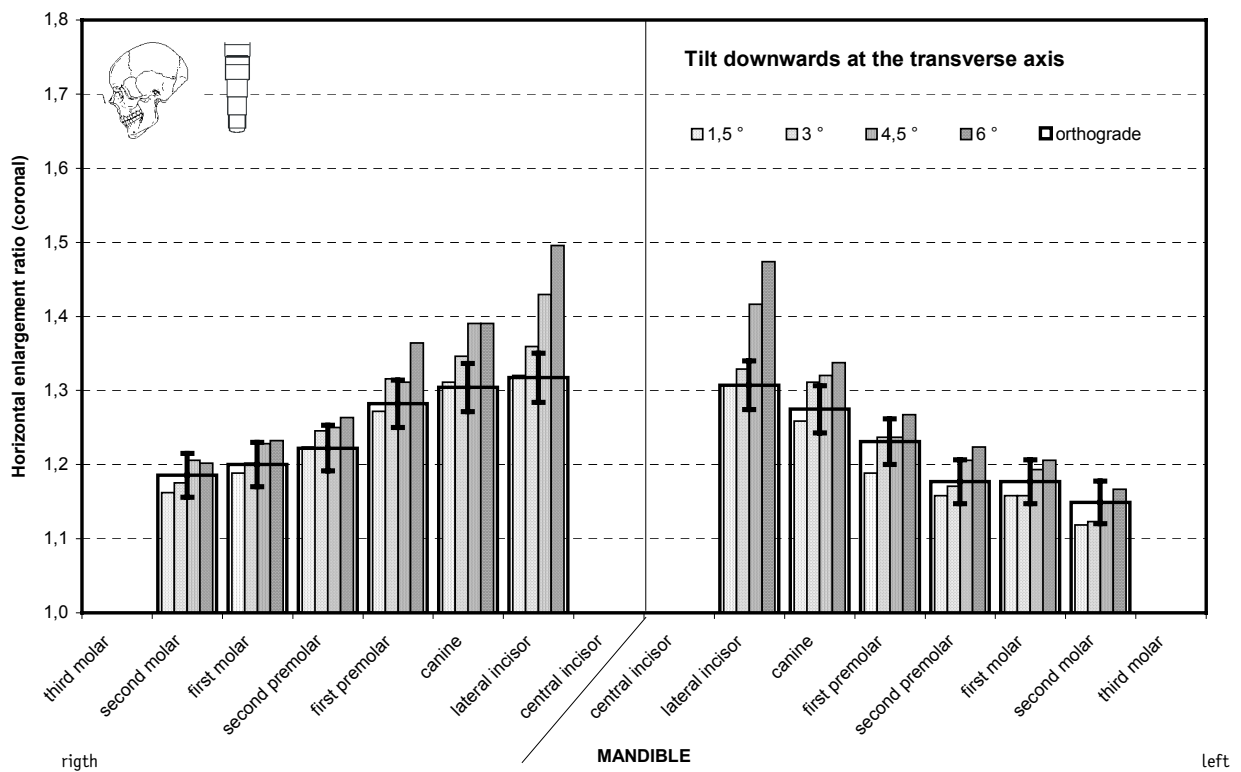
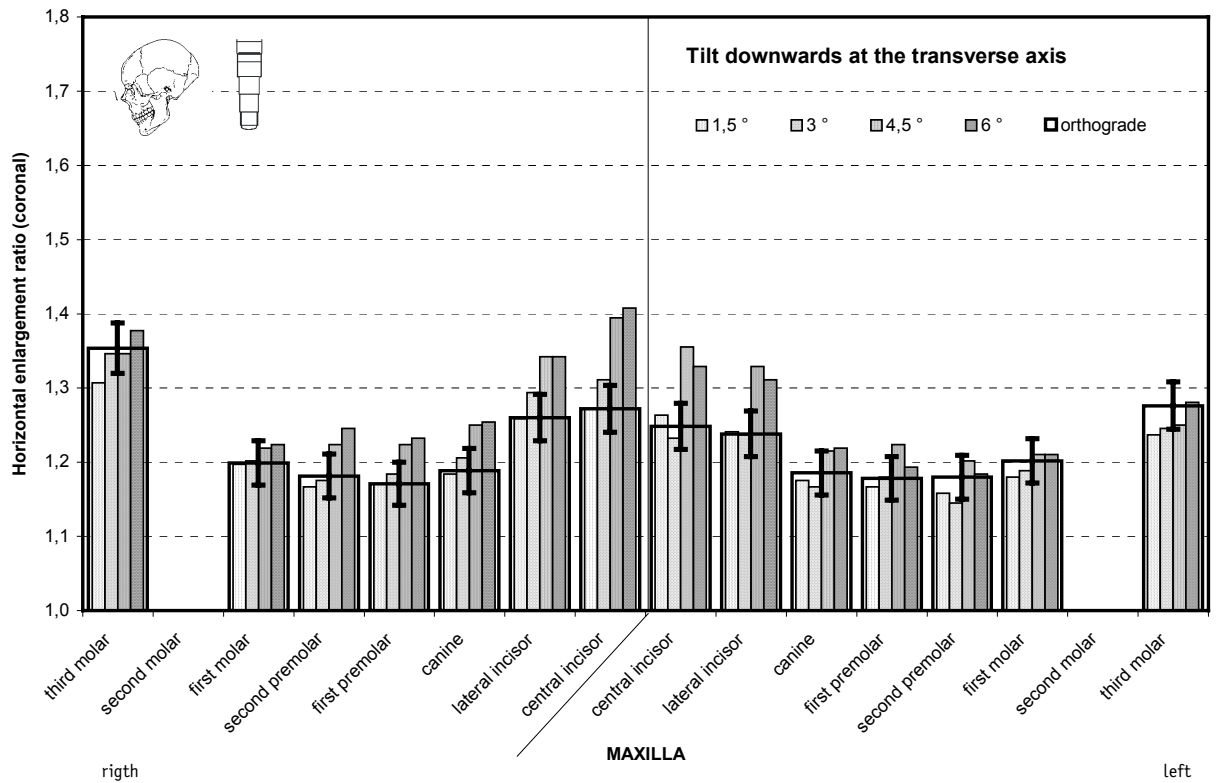


Fig. 8 Average horizontal magnification at the coronal end of the implant on *tilt downwards at the transverse axis*. The display corresponds to Fig. 7. The reproducibility of the settings at the x-ray apparatus is 5%.